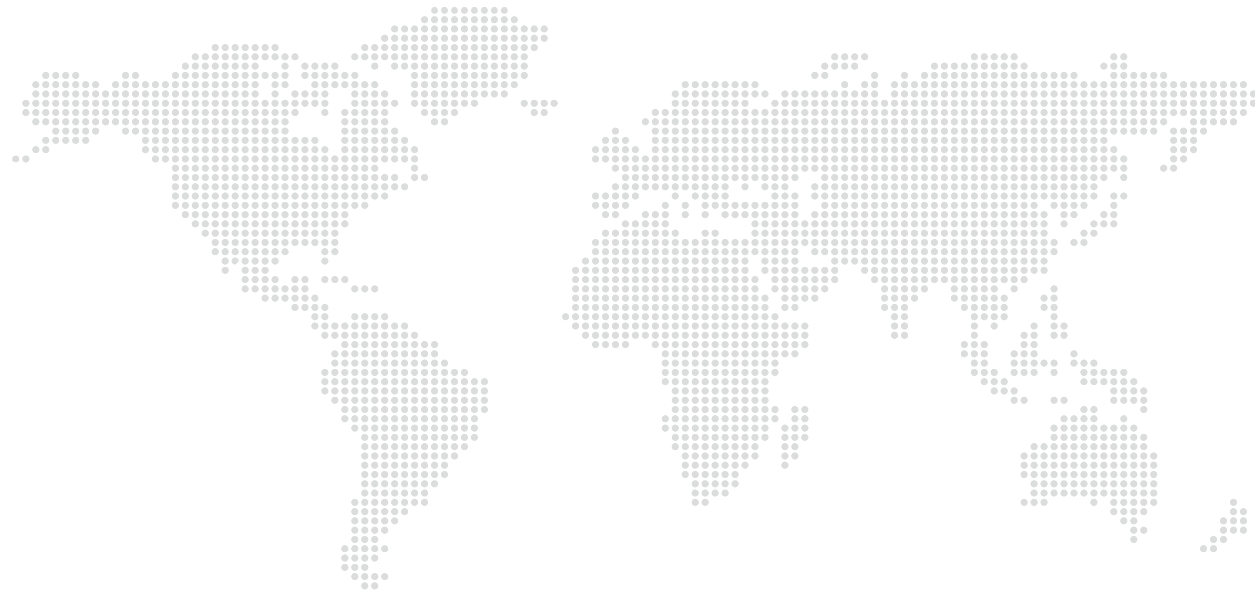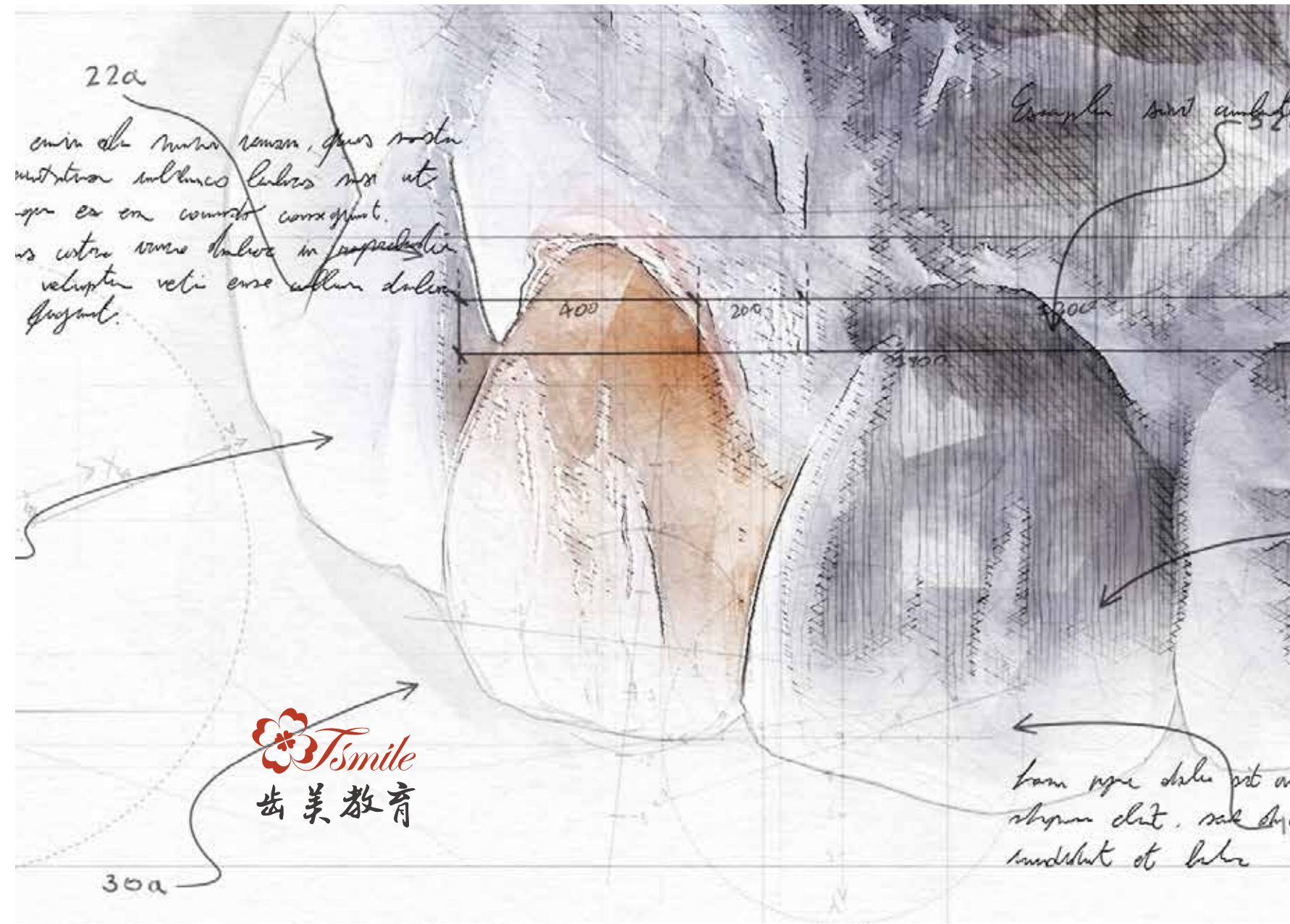


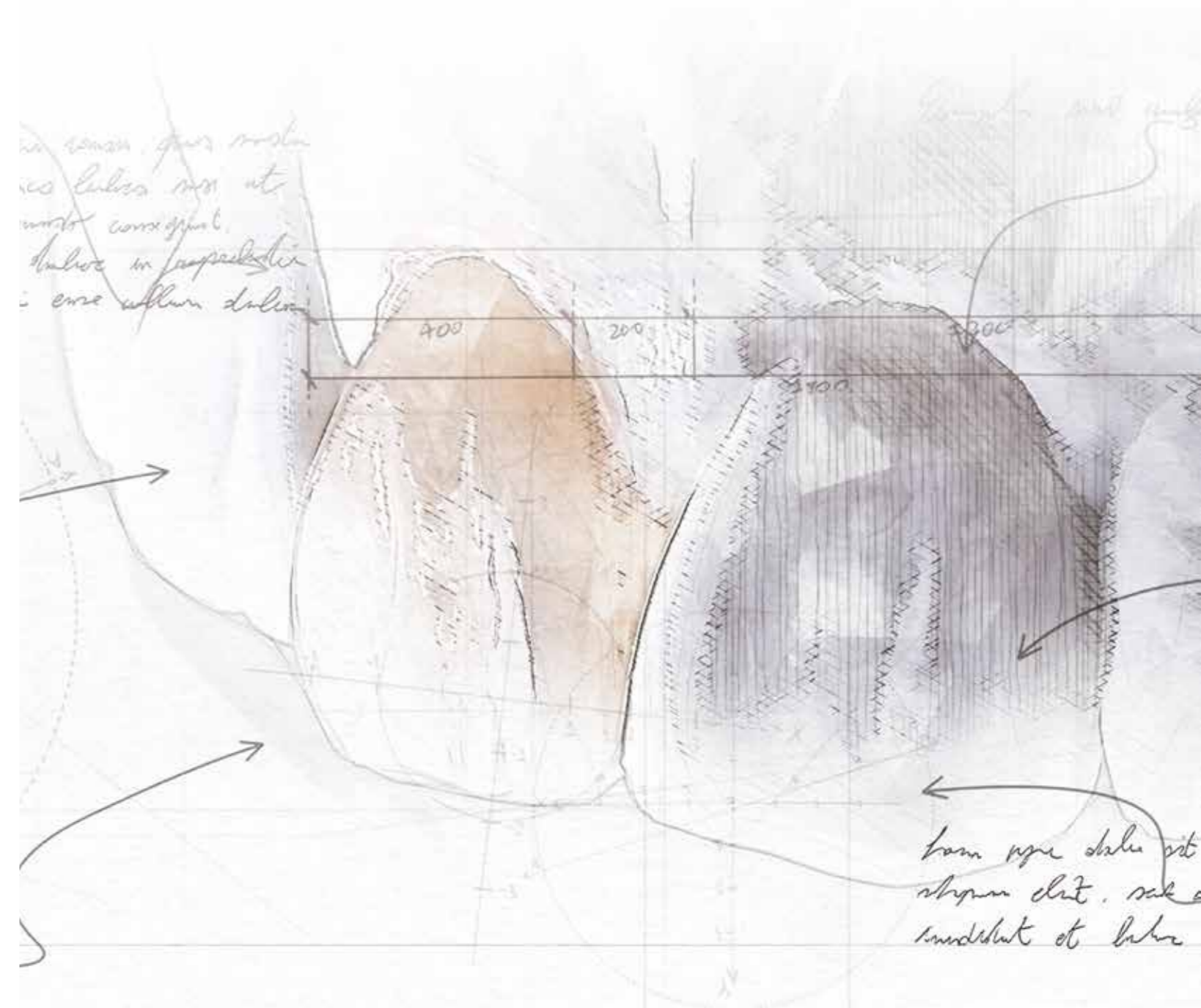


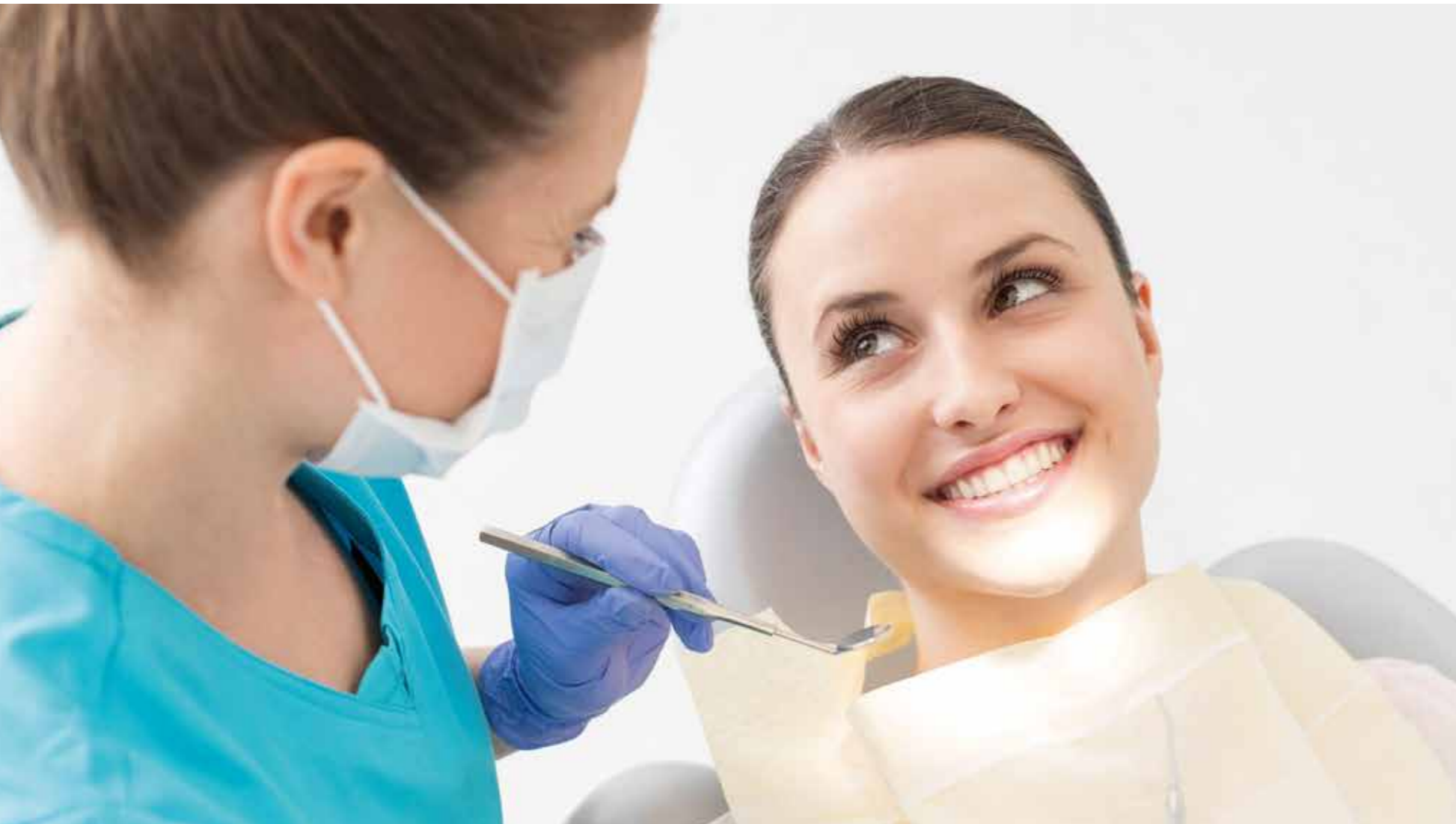A MULTICENTER CLINICAL STUDY OF ALL-CERAMIC AESTHETICS

A MULTICENTER CLINICAL STUDY OF ALL-CERAMIC AESTHETICS



A MULTICENTER CLINICAL STUDY OF ALL-CERAMIC AESTHETICS





Project Overview

The Multi-center All-ceramic Aesthetics Clinical Research Project, initiated by Tsmile and Upcera, has called a cohort of experts and dentists from different cities around China to present this delicate clinical case series. Jointly endeavours made by dentists, technicians, and dental enterprises, this project demonstrates the excellence of "Made-in-China" all-ceramic materials, promotes their usages, and promotes the development of Chinese stomatological undertakings.

CONTENT

Expert group	01
Research team members	03
Support partners	05
Zirconia ceramic cases	07
Resin-matrix ceramic cases	20

EXPERT GROUP



Prof. Jianguo Tan

Peking University School of Stomatology



Prof. Cong Fan

Peking University School of Stomatology



Prof. Feng Sun

Peking University School of Stomatology



Prof. Jianjun Yang

The Affiliated Hospital of Qingdao University



Prof. Zhe Wu

Stomatology Hospital of Guangzhou
Medical University



Prof. Xu Gao

School of Stomatology Shandong University



Prof. Cui Huang

Hospital of Stomatology Wuhan University



Prof. Xiaodong Chen

Dalian Stomatological Hospital



Prof. Chufan Ma

Characteristic Medical Center of Air Force Medical University



Prof. Xinchun Zhang

Guanghua School of Stomatology Hospital of Stomatology



Prof. Xiaoang Ye

The School of Stomatology of
Fujian Medical University



Prof. Liqiang Xu

Shenzhen People's Hospital

RESEARCH TEAM MEMBERS



Dandan Wang

Affiliated Hospital of Jining Medical College



Fangping Wang

Affiliated Hospital of Qingdao University



Haibao Wang

Qingdao Laoshan Haibao Dental Clinic



Jifen Chen

Dalian Stomatological Hospital



Ranran Chen

The First Affiliated Hospital of Medical
College of Zhejiang University



Yanyun Chen

Xiamen Siming Liangde Oral Clinic



Hao Wang

Nanjing Xuanwu Tongren Street
Community Health Service Center



Mei Wang

Guiyang Oral Hospital



Weiliang Wu

The School of Stomatology of
Fujian Medical University



Yu Chen

Dongying Shengli Oilfield Center Hospital



Dong Lin

Shandong University Oral Hospital



Xiaoqiang Liu

Peking University School of Stomatology



Hong Yang

Guiyang Oral Hospital



Min Zong

Dongying Shengli Oilfield Center Hospital



Yong Zhang

Shijiazhuang Second Hospital



Deli Li

Peking University School of Stomatology



Cong Lin

Dongying Shengli
Oilfield Center Hospital



Yi Luo

Guiyang Oral Hospital



Guanghui Ren

Yantai Oral Hospital Affiliated to
Binzhou Medical College



Kunpeng Zhou

The Affiliated Hospital of
Qingdao University



Rui Zhou

Dongying Shengli Oilfield
Center Hospital



Xiao Zeng

Guizhou Medical University
School of Stomatology



Mengmeng Zhang

Dongying Shengli Oilfield
Center Hospital

SUPPORT PARTNERS



Tsmile is a global leading content provider, platform provider technology and service provider based in China that integrates dental medical management professional dentist training and dental medicine

Tsmile was created by several well-known dental experts and gathered the elite dental experts both domestic and global

To spread the advanced dental concepts and techniques to help the growth of dentists worldwide

Taking the promotion of more efficient and high-quality dental medical services as our mission

Launch courses with fruitful contents in various forms, and take advantage of the "Internet +" trend to build an online teaching platform and offline curriculum system in an all-round way

We are good teacher and helpful friend for dentists

We make everyone smile more confident with healthy teeth

齿美教育 分享成长

SHARE THE GROWTH WITH TSMILE



<http://www.tsmileedu.com>



Zhenzhi (Dalian) medical equipment Co., Ltd.



Misu Aesthetics



Yougen dental medical technology (Beijing) Co., Ltd.



New Perfect Dental Group



Shanghai raparo denture Co., Ltd.



Shang Hai A H

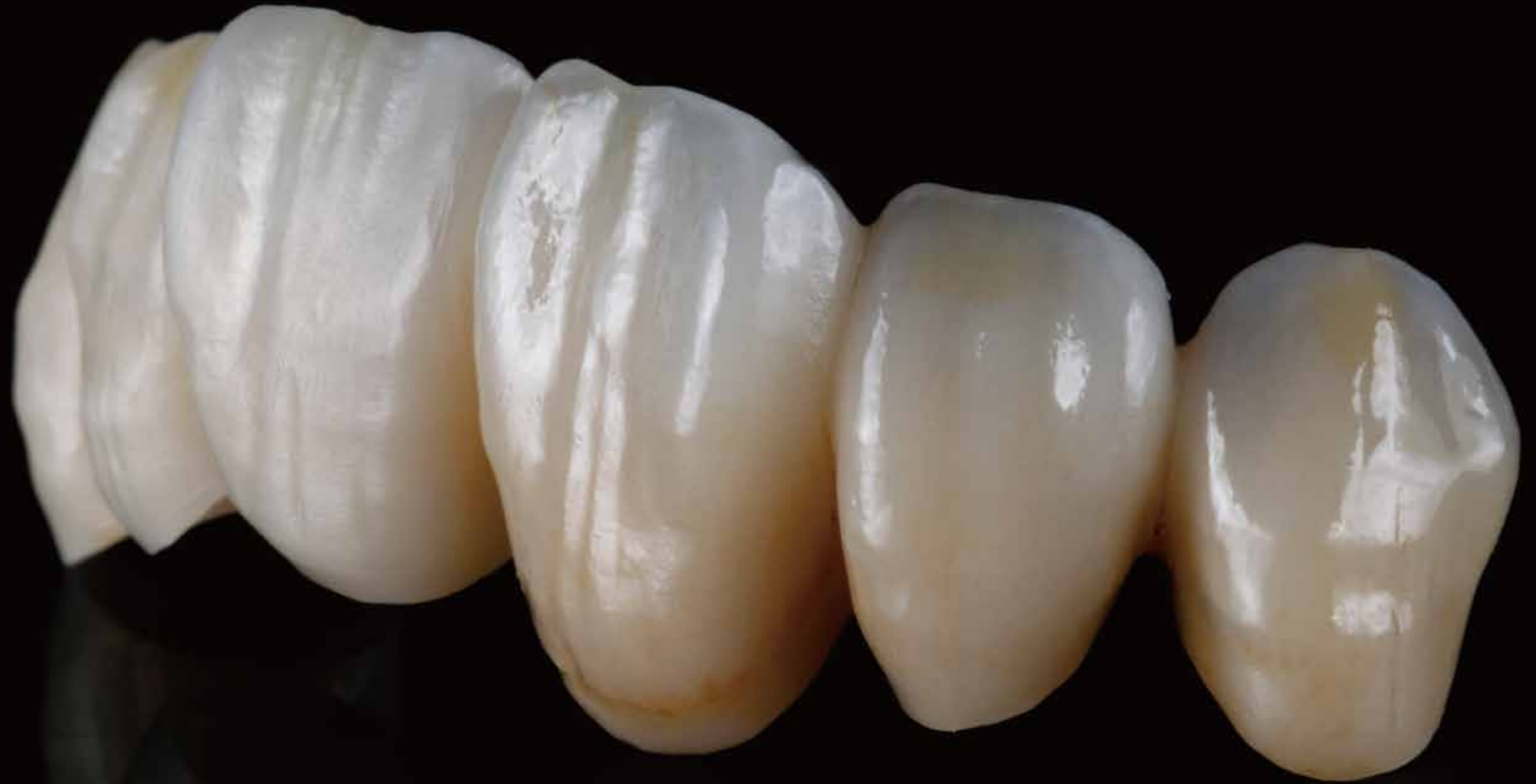Looking forward to more support partners to join >>

To support, please: (+86)13911309902



ZIRCONIA CERAMICS

CASE PRESENTATION





Jianguo Tan | Peking University School of Stomatology

Professor / Chief dentist / Doctoral supervisor
Minister of Continuing Education Department of Chinese Stomatological Association
Founding Chairman and Vice Chairman of CSED
Member of the Standing Committee of Prosthodontics Committee of Chinese Stomatological Association
Standing director of Beijing Medical Cosmetology Specialist Branch of Beijing Medical Association
Member of the American Association of Fixed Prosthodontics

Basic information of the patient Gender: Male Age: 28 years old

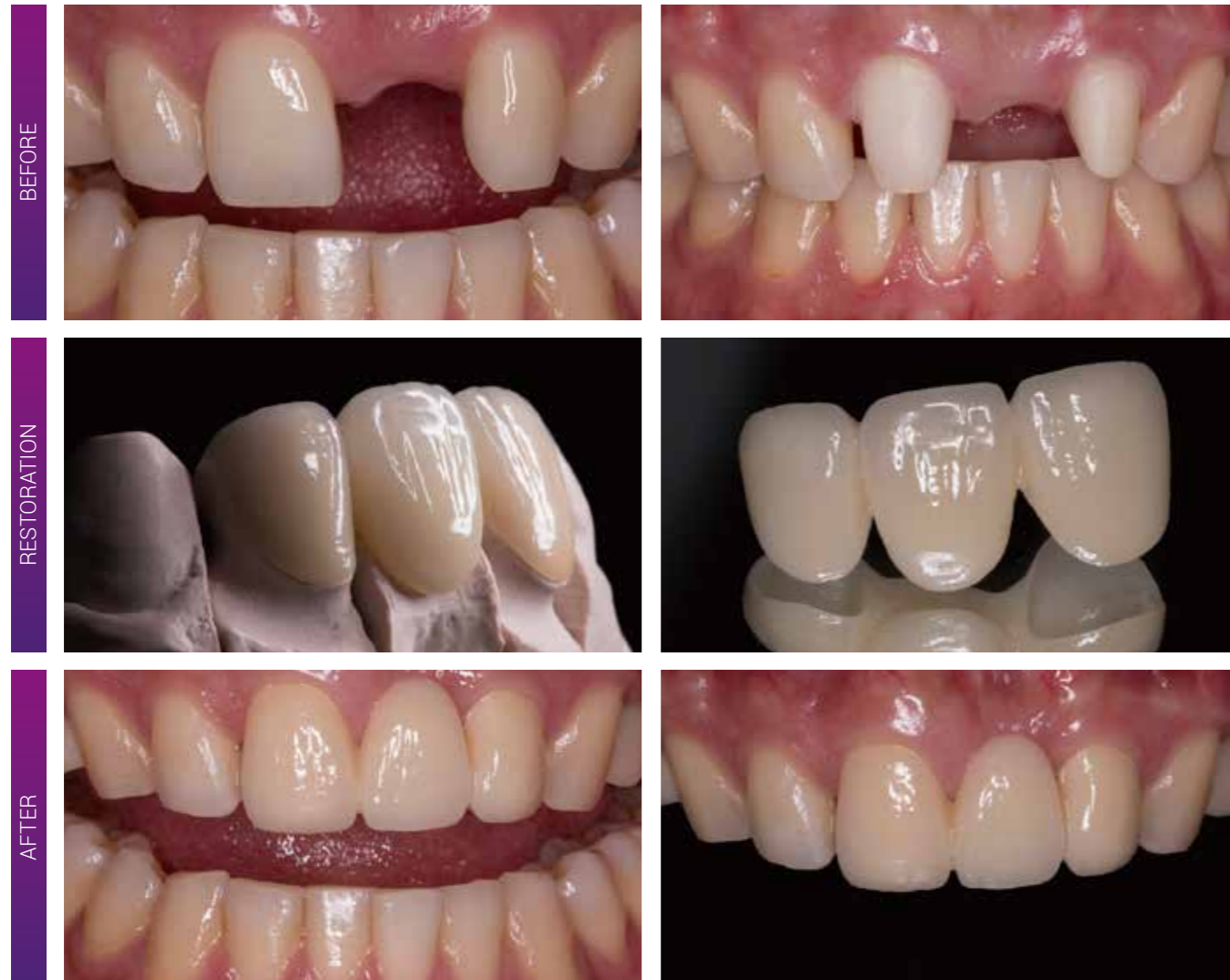Chief complaint: Left anterior tooth missing.

Diagnosis: Defect of upper dentition.

History of present disease: Left anterior tooth has been missing for many years. The patient would like to improve esthetics, but refuses implant restorations.

Treatment plan: 11-22 fixed bridge restoration.

Material choice: High translucency zirconia (Explore, Upcera, China).





Dong Lin | Shandong University Stomatological Hospital

Dentist
Youth member and working secretary of CSED

Basic information of the patient Gender: Female Age: 44 years old

Chief complaint: Requires aesthetic restoration of anterior teeth.

History of present disease: The patient had been wore a fixed bridge for 12 years, and are now seeing new restorations due to unpleasant smiles. Her upper anterior teeth were adjusted and grinded.

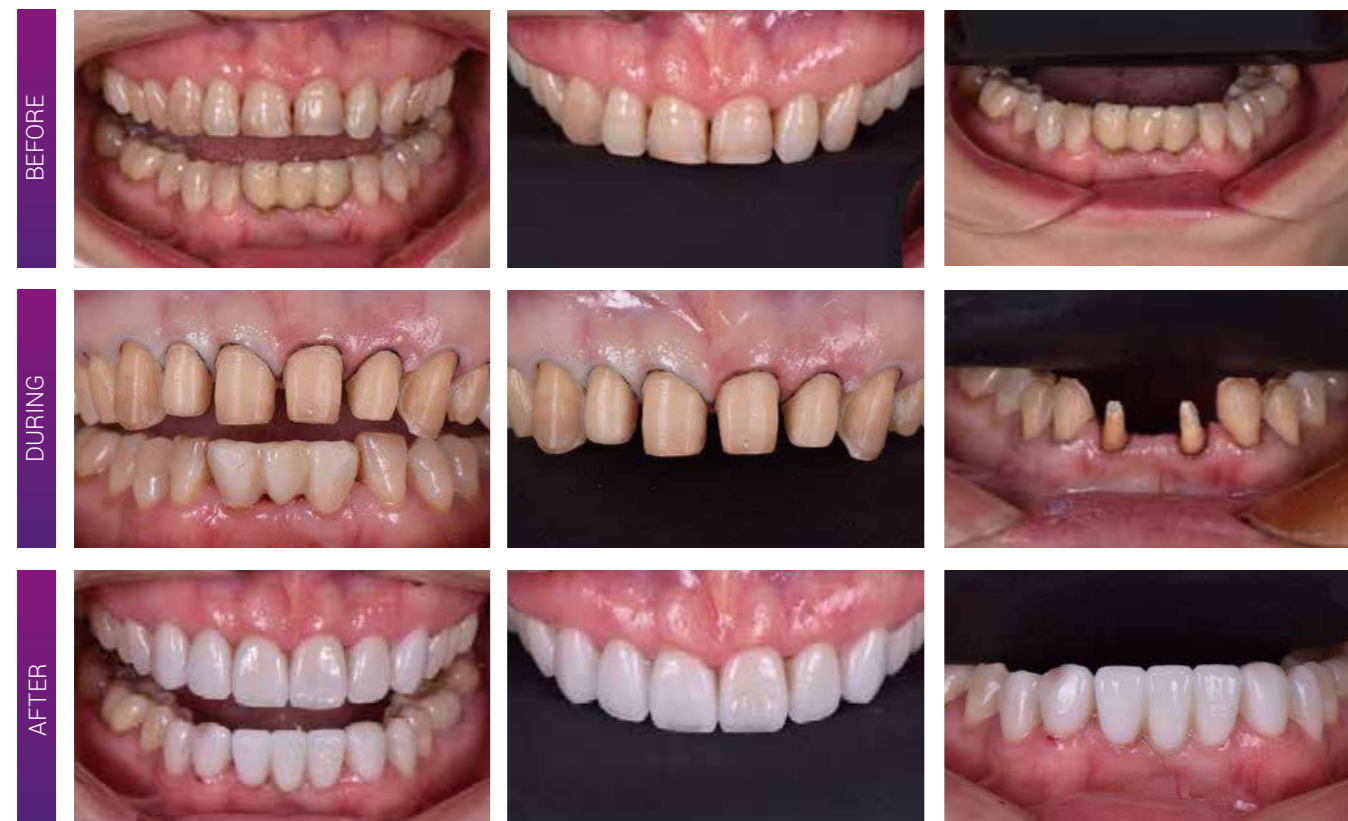Examination: The shape and color of the 32-42 PFM-fixed bridge prosthesis were not good. The prosthesis is ill fitted. The incisor margin of teeth 11-21 was partially defective. The whole teeth were stained with tetracycline, and the front teeth were not arranged properly. Teeth 12 and 13 are mildly twisted. There are black triangular space between 11 and 21. No loose or percussion symptoms on the rest of the teeth.

X-ray examination: 32, 42 teeth had received root canal treatment, No abnormality was observed in the apical area, no root canal treatment was performed on teeth 14-24, 33-34, and 43-44, and no obvious abnormality was observed in the apical area.

Diagnosis: 32, 42, 11, 21 dental defects.

Treatment plan: 14-24, 33-34, 43-44 veneer and 32-42 fixed bridge.

Material selection: High translucency zirconia(Explore, Upcera, China), glass ceramics (UP-Cad, Upcera, China).



EXPERT REVIEW

Huang Cui | Hospital of Stomatology Wuhan University

Professor / Chief dentist
Director of Wuhan University Stomatological Hospital Prosthodontics Department
Vice Chairman of CSED
Vice Chairman of the Prosthodontics Committee of the Chinese Association of Stomatology
Chairman of the Oral Aesthetics Committee of Hubei Stomatological Association
Deputy Chairman of the Oral Prosthodontics Committee of Hubei Dental Association
Deputy Head of Oral Prosthetics Group, National Medical Examination Center

Comments:

1. Dr. Lin's case represents the common aesthetic defects of tooth hard tissue, such as abnormal color, tooth defect, abnormal spatial arrangement, etc., and the case is highly difficult. After all-porcelain veneer, all-porcelain crown and all-porcelain bridge restoration treatment, good aesthetic effect has been achieved. The abnormal tooth color was well resolved, especially the gingival condition was well recovered during the revisit, which is crucial for long-term stable esthetic outcome. It is suggested to further standardize the description of chief complaint and highlight the three elements of chief complaint: location, symptoms and time. In the diagnostics section, the color abnormality diagnosis should be added.
2. The veneer repair effect can fully reflect the excellent aesthetic repair effect of lithium porcelain. The lower anterior area of the tooth Upcera Explre all-ceramic zirconia was chosen for the lower anterior area under the consideration of strength and esthetics, which implies suitable choice with multilayer gradient zirconia for anterior teeth restorations.



- Suitable for all indications



Ranran Chen | The First Affiliated Hospital of Medical College of Zhejiang University

Dentist

Member of Zhejiang Prosthodontics Professional Committee

Basic information of the patient Gender: Female Age: 28 years old

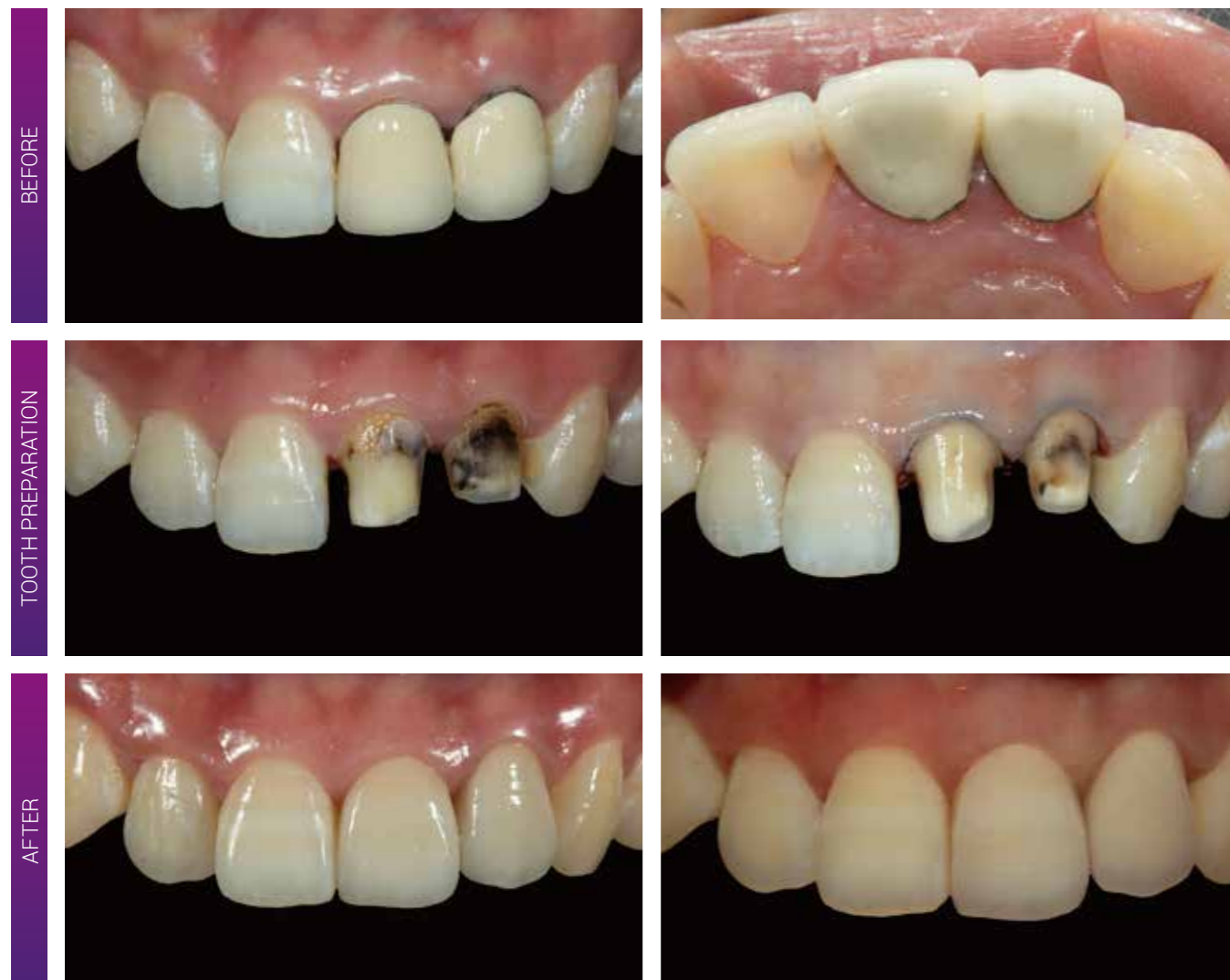Chief complaint: Discoloration of the porcelain teeth of the upper anterior teeth and receding gums for 1 year.

History of present illness: 8 years ago, the patient underwent a porcelain crown restoration of the upper anterior teeth. 1 year ago, it was discovered that the restoration was discolored and the gums receded.

Diagnosis: 21 and 22 tooth defects.

Treatment plan: 21, 22 full crown restorations.

Material selection: High translucency zirconia (Explore Esthetic, Upcera, China).



EXPERT REVIEW

Cong Fan | Peking University School of Stomatology

Consultant dentist

Member of the Standing Committee of CSED

Member of the Editorial Board of the Chinese Journal of Medical Aesthetics and Cosmetology

Member of the expert group of the National Medical Examination Center

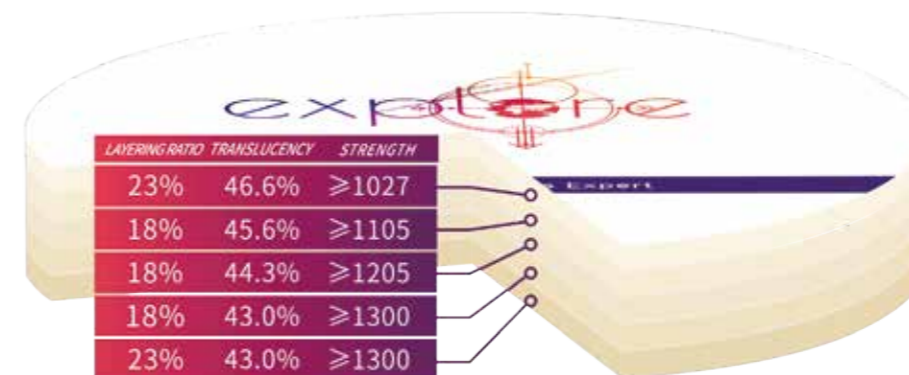
Expert of medical accident technical appraisal of Beijing Medical Association

Comments:

1. This case is a secondary restoration of all-ceramic crowns for patients with anterior tooth defects. The treatment design is reasonable and the selected restoration materials meet the relevant standards. After restoration, the clinical performance is good, especially the color performance is very close to the natural tooth. The layering of the crown and the translucency of the incisal edge are the similar to those of the adjacent tooth which make a great clinical effect. Disadvantages: The position of the gingival margin of the lateral incisor is not symmetrical to that of the contralateral tooth with the same name.

2. When making all-ceramic crown restoration in the anterior tooth area, material selection includes: porcelain fused to zirconia (PFZ), glass-based full-anatomical ceramic crown or glass-based inner crown with decorated porcelain and so on, as the translucency of zirconia material increases, high translucency zirconia can also be used for restoration.

Aesthetic effect: glass-based inner crown decorated with porcelain>glass-based full-anatomical porcelain crown=porcelain fused to zirconia (PFZ). PFZ is recommended for patients with higher requirements for the aesthetic performance of the incisal edge.





Weiliang Wu | The First Affiliated Stomatological Hospital of Fujian Medical University

Dentist
Young lecturer of the Oral Aesthetics Professional Committee of the Chinese Stomatological Association
Member and Secretary of the Standing Committee of the Aesthetics Committee of the Fujian Stomatological Association

Basic information of the patient Gender: Female Age: 17 years old

Chief complaint: The discoloration of the upper anterior teeth, requires full crown restoration.

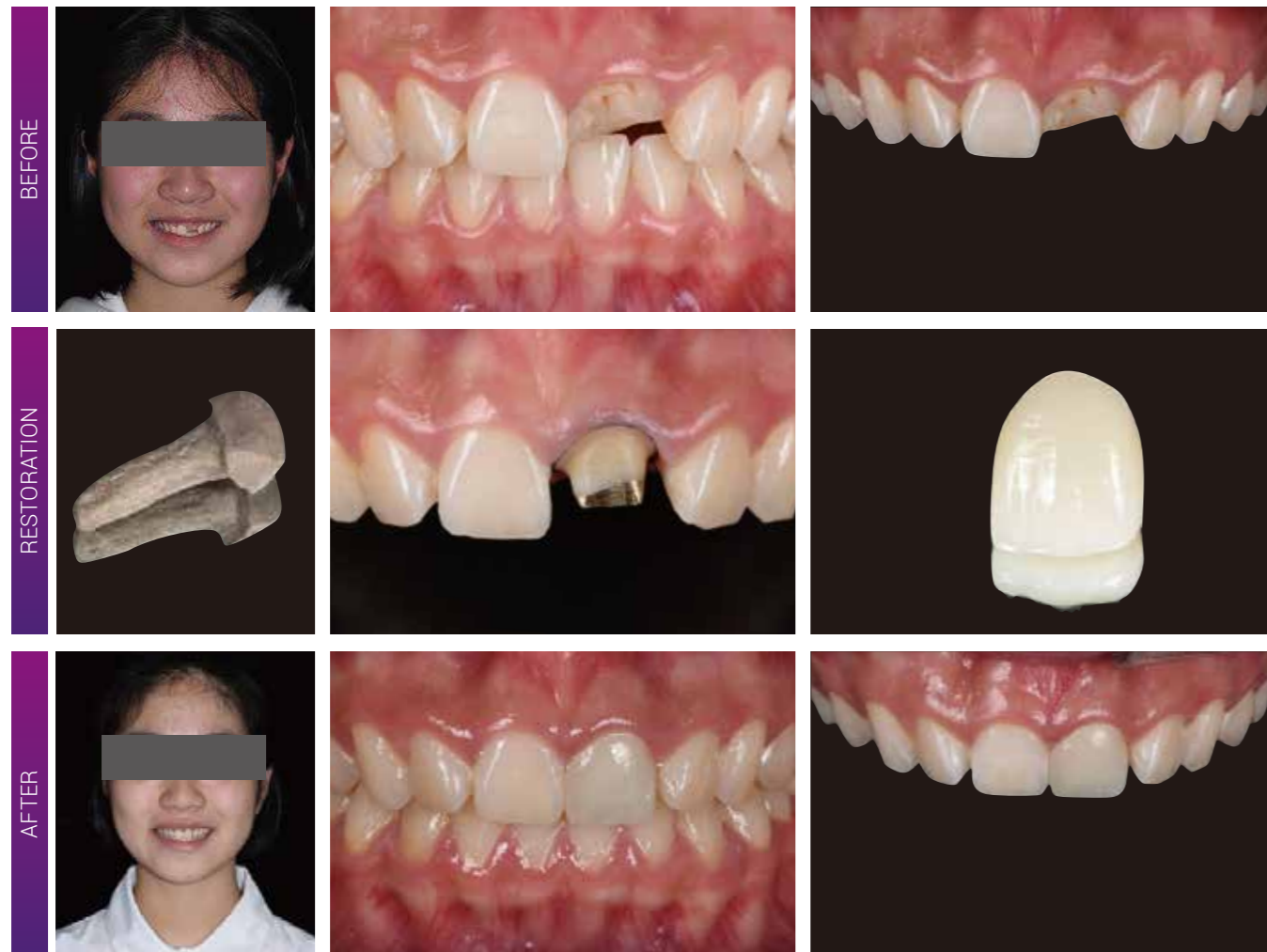
History of present illness: The patient had a traumatic crown fracture 8 years ago and received RCT treatment 2 years ago. Patient required a full crown restoration to solve the teeth's discoloration.

Examination: 21 teeth palatal composite resin filling, percussion pain (-), no looseness, gums (-), X-ray film showed that 21 teeth were finished Good root canal treatment, no obvious abnormality in the root tip.

Diagnosis: 21 tooth defects.

Treatment plan: 21 post-core crown restoration.

Material selection: High translucency zirconia (Explore Esthetic, Upcera, China).



EXPERT REVIEW

Xu Gao | School of Stomatology Shandong University

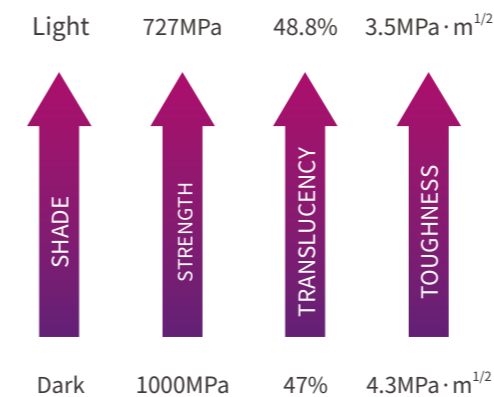
Chief dentist / Director of Prosthodontics Department
Reviewer of "Stomatology" magazine
Expert of medical accident appraisal of Shandong Provincial Health and Family Planning Commission
Expert of project review of Shandong Provincial Department of Science and Technology Member and Secretary of CSED
Member of the Standing Committee of the Oral Prosthodontics Committee of the Chinese Association of Stomatology
Vice Chairman of Oral Prosthetics Professional Committee of Oral Plastic Surgery Branch of China Plastic Surgery Association
Vice Chairman of Shandong Provincial Oral Aesthetics Committee
Member of Standing Committee of Shandong Oral Prosthetics Professional Committee



Comments:

1. Dr. Wu Weiliang's case is a post-core crown restoration of maxillary central incisor defect and discoloration. After the post-core restoration, the satisfactory clinical results have been achieved. This kind of discolored teeth can be considered for pre-bleaching. In addition, the height of the prepared teeth is greater than 1.5mm from the picture, also can choose fiber core and glass-based all-ceramic crown restoration to achieve a better result. Another point is that the gingival papilla of the two incisors are slightly red and swollen.

2. The restoration type of this case is high translucency zirconia (Explore) + fused procelain. It can meet the strength and aesthetic requirements for anterior tooth restoration, and its translucency is better than traditional zirconia. The discolored tooth tissue and the gold-palladium post core affect the restoration effect, and the aesthetic effect can be improved by color masking of the inner crown.





Mengmeng Zhang | Dongying Shengli Oilfield Central Hospital

Dentist

Basic information of the patient Gender: Female Age: 26 years old

Chief complaint: Request to repair the defect of the maxillary right premolar(15).

History of present illness: The patient requested restoration after root canal treatment.

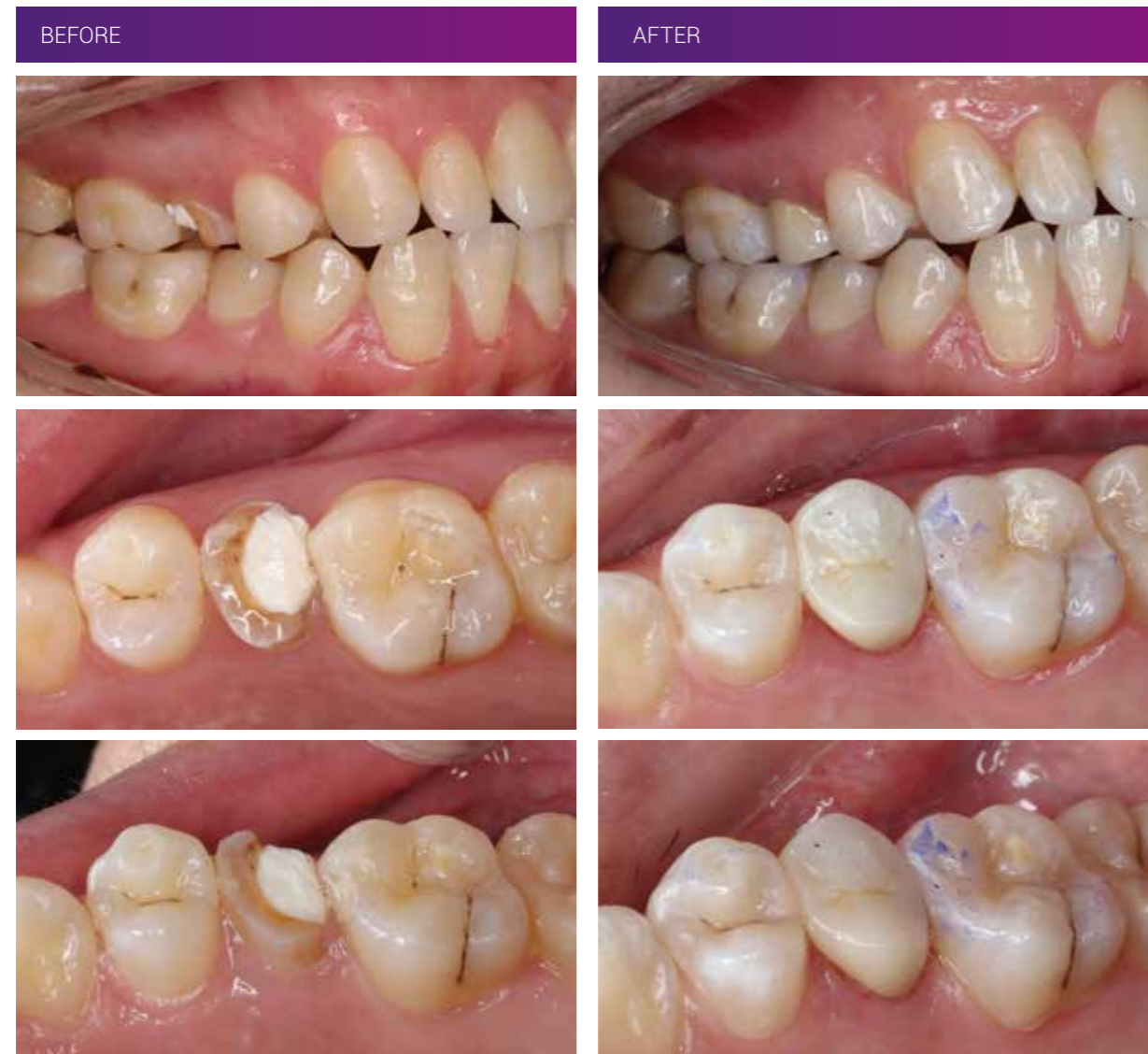Examination: The distal and occlusal defects of maxillary right premolar(15), temporarily sealed. The distal defect extends to the gingiva.

Periodontal and gums are in good condition.

Diagnosis: defective restoration(15).

Treatment plan: post-core restoration(15).

Material selection: high translucency zirconia (Explore, UPCERA, China).



EXPERT REVIEW

Jianjun Yang | The Affiliated Hospital of Qingdao University

Professor / Chief dentist

PhD Supervisor

Member of the Oral Implant Committee of the Chinese Stomatological Association

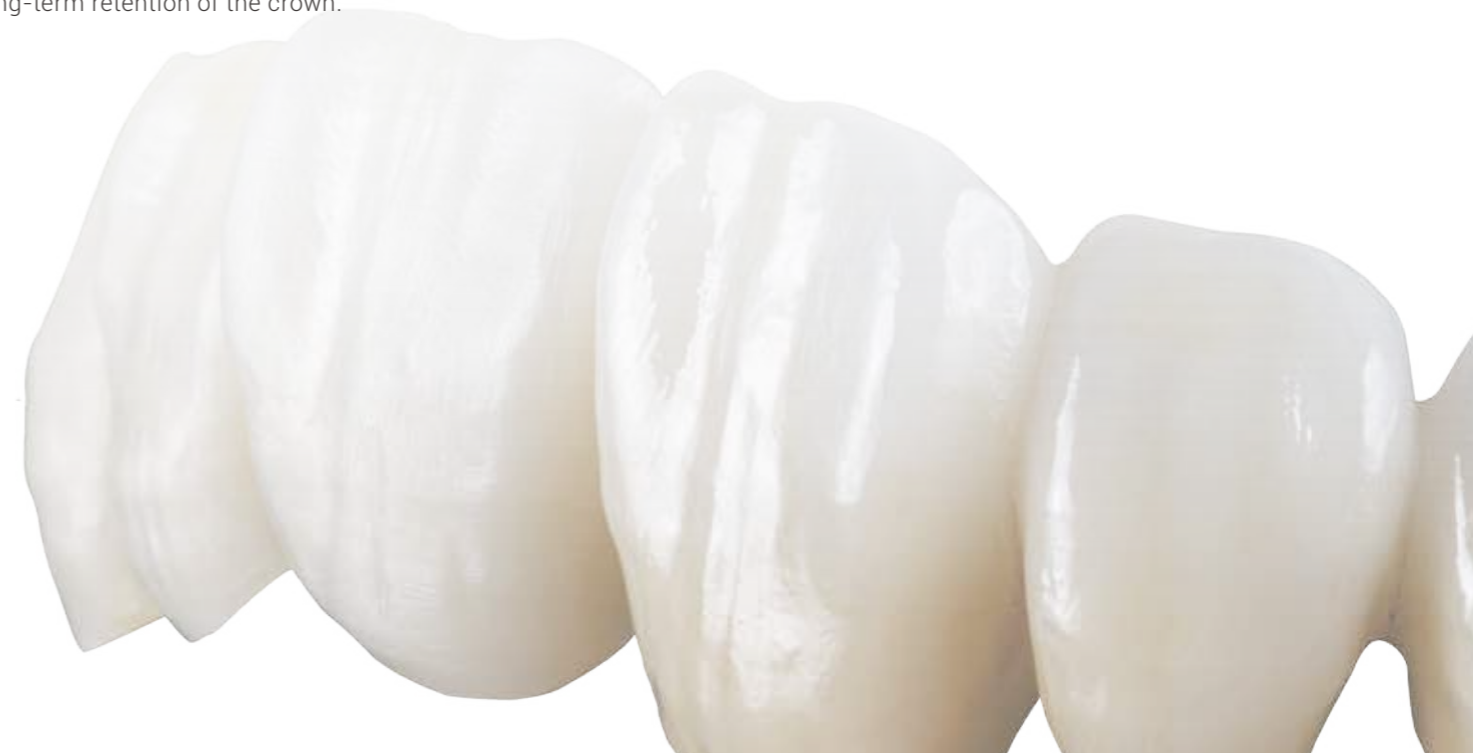Vice Chairman of Qingdao Stomatological Association

Vice Chairman of the Oral Implant Specialty Committee of Qingdao Stomatological Association

Comments:


1. In this case, 15 premolar has large-area defects, and it is more appropriate to repair by post-core method. The cervical area is not strong enough when the premolars are subjected to lateral stress. It should be noted that the ideal choice of post is in gold made. Golden post can transmit force to the root tip when subjected to stress, and play a certain protective role for the weaker cervical area.

2. In this case, the height of crown(15) was relatively low, so a full contour zirconia crown (UPCERA, Explore) was chosen. It is conducive to retaining more remaining tooth tissue. Moreover, UPCERA Explore zirconia has five main different layers and nine transition layers, which is an ideal material that can take into account both aesthetics and function. However, it is necessary to pay attention to the problem of poor adhesion of zirconia when the crown height is insufficient. At the same time, pay attention to occlusal adjustment, to reduce the lateral force as much as possible to maintain the relatively long-term retention of the crown.



GLASS-MATRIX CERAMICS

CASE PRESENTATION





Xiaoqiang Liu | Peking University School of Stomatology

Associate Professor
Dentist
Youth member and working secretary of Oral Aesthetics Special Committee of Chinese Stomatological Association

Basic information of the patient Gender: Female Age: 31 years old

Chief complaint: request to fix the front teeth due to their poor aesthetics.

History of present illness: discoloration of maxillary and mandibular anterior teeth.

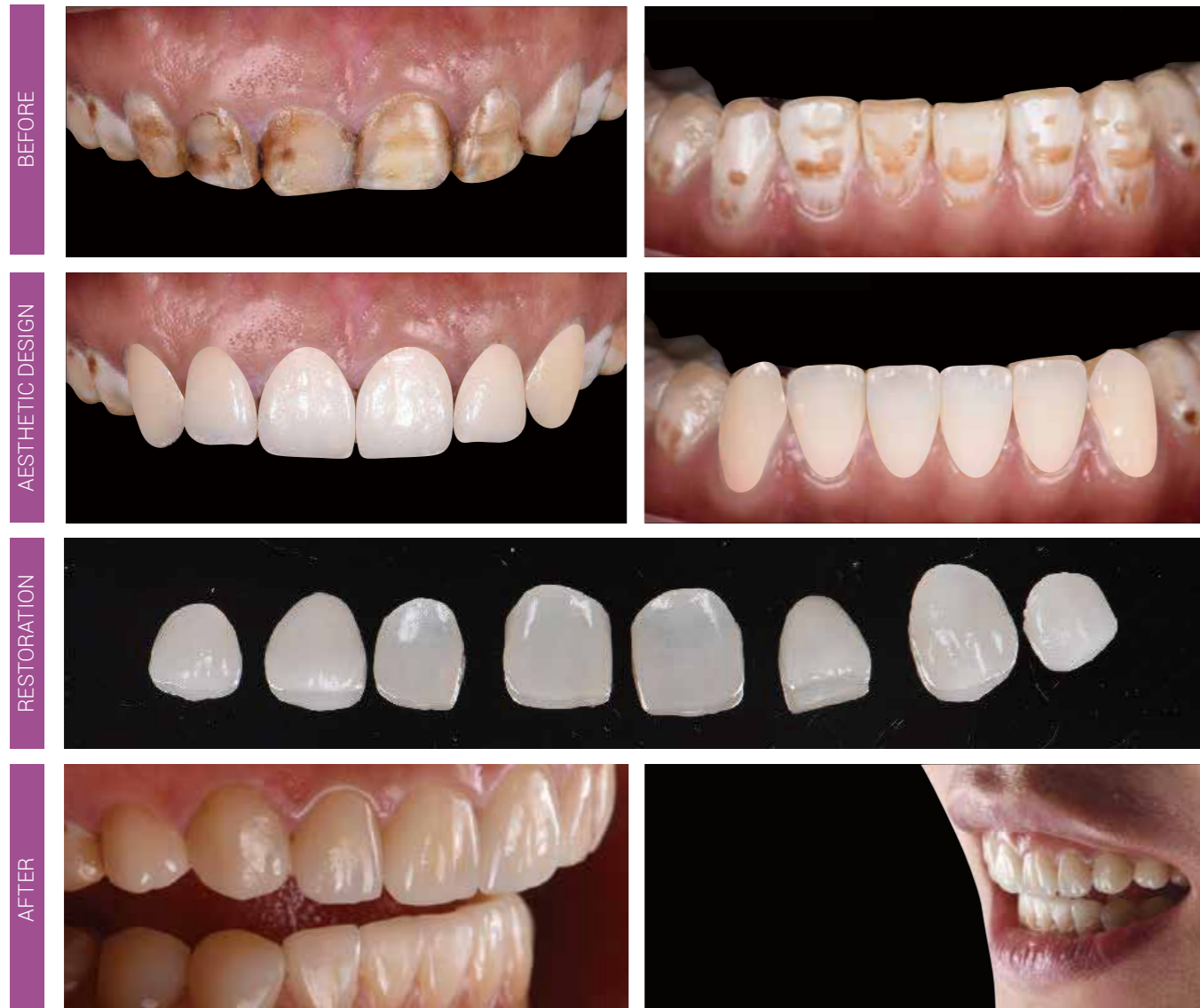Examination: attrition of labial enamel and incisal edge of maxillary and mandibular teeth(4-4), discoloration.

The periapical radiograph showed that there was no root filling and the periodontal ligament image was clear.

Diagnosis: dental fluorosis.

Treatment plan: 14-24, 34-44 porcelain laminate veneer.

Material selection: Glass ceramics (lithium disilicate, Upcera, China).



EXPERT REVIEW

Xiaodong Chen | Dalian Stomatological Hospital

Professor / Chief dentist / Dean
Member of the Chinese Association of Stomatology
Member of the Standing Committee of the Stomatologist Branch of the Chinese Medical Doctor Association, Academician of the International College of Dentistry
Member of the Standing Committee of CSED
Member of the Standing Committee of the Professional Committee of Prosthodontics, Chinese Association of Stomatology
Vice President of Liaoning Provincial Stomatological Association, former Chairman of Professional Committee of Prosthodontics of Liaoning Provincial Stomatological Association
Chairman of the Oral Aesthetics Professional Committee of the Liaoning Stomatological Association
Chairman of Dalian Medical Association Dental Specialist Branch
Director of Dalian Dental Medical Quality Control Center

Comments:

1. In this case, the teeth have aesthetic defects in color and shape. The doctor clarified the final aesthetic restoration goal and used the software to achieve a two-dimensional aesthetic design before the operation. In the treatment, the precise restoration concept of 'begin with the end' was implemented, and satisfactory aesthetic restoration results were obtained. In addition, the veneer restoration method is able to preserve the healthy tooth tissue to the greatest extent. To prepare the teeth with aesthetic goals, make sure the minimum grinding and retain as much enamel bonding substrate as possible to ensure the long-term prognosis of the restoration.

In this case, the influence of the lengthening of the maxillary anterior teeth on the incisal area should be concerned.

2. All-ceramic materials that can be used for porcelain laminate veneer mainly include feldspathic glass ceramics, leucite-reinforced glass ceramics and lithium disilicate-reinforced glass ceramics.

The lithium disilicate glass ceramic used in the case has good translucency and mechanical strength, ensuring a good aesthetic effect.

In addition, the surface of the glass-based ceramic can be roughened with hydrofluoric acid to form a micromechanical interlocking, coated with a silane coupling agent, and form a chemical bond with the resin cement to ensure a long-term stable bonding.





Deli Li | Peking University School of Stomatology

Dentist

Director of the Prosthodontics Department of the Second Clinic

Youth member and working secretary of Oral Aesthetics Special Committee of Chinese Stomatological Association

Basic information of the patient Gender: Female Age: 31 years old

Chief complaint: Patient requires to restore the upper anterior teeth.

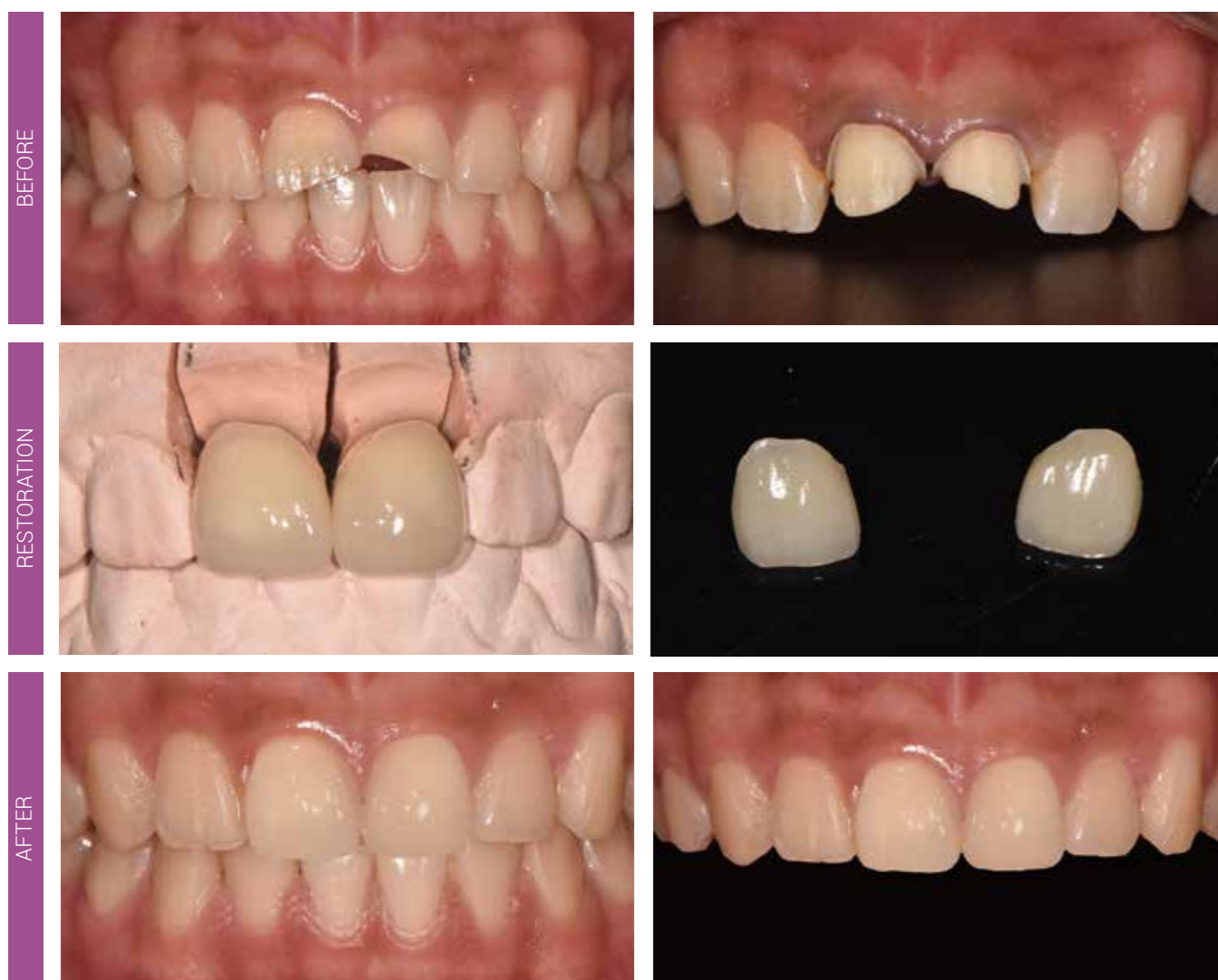History of present illness: Upper anterior teeth injured 2 years ago. Looking for natural and aesthetic restorations.

Examination: #11 #21 crown medium tooth defect, the defect extend to 2mm above gingival on palatal side. No obvious loosening, precussion and gingival swollen.

Diagnosis: #11 #21 teeth fracture.

Treatment Plan: #11 #21 venner restoration.

Material selection: Glass ceramics (lithium disilicate, Upcera, China).



EXPERT REVIEW

Zhe Wu | Stomatology Hospital of Guangzhou Medical University

Professor / Chief dentist / Director of Prosthodontics Department

Member of the Standing Committee of CSED, Member of the Standing Committee of the Oral Prosthodontics Committee of the Chinese Stomatological Association

Member of the Standing Committee of Guangdong Prosthodontics Committee, Member of the Standing Committee of Guangdong Dental Education Committee

Comments:

1. The overall case is well completed, and the result before and after restoration is very obvious.

But there are still two suggestions as follows:

①The description of the main resort should include the location, time and symptoms. It is not recommended to write "request to restore the upper anterior teeth."

②Whether the choice of veneer restoration is appropriate in this case? The veneer is more suitable for small tooth surface defects or anterior incisal angle defects. For this case, #21 defects exceeds 1/2 of the length of the tooth. There might be debonding risks under the huge occlusal force.

2. Upcera lithium disilicate are selected for this case. It is not specified whether it is manufactured by CAD-CAM or heat-pressed. The material selection is consistent with Indications for clinical application of combined glass ceramics. However, the transparent color of the prepared abutment is clearly visible on the model. I don't know how to avoid it when bonding? The results reflect lithium disilicate can be used for anterior tooth veneer restoration to obtain a good restoration effect.



UP.CAD

- Excellent Mechanical Strength
- Brilliant Aesthetics with Super High Translucency
- Chairside Instant Restoration



Weiliang Wu | The First Affiliated Stomatological Hospital of Fujian Medical University

Dentist
Young lecturer of the Oral Aesthetics Professional Committee of the Chinese Stomatological Association
Member and Secretary of the Standing Committee of the Aesthetics Committee of the Fujian Stomatological Association

Basic information of the patient Gender: Male Age: 34 years old

Chief complaint: Detached upper PFM crowns, seeking for new restorations.

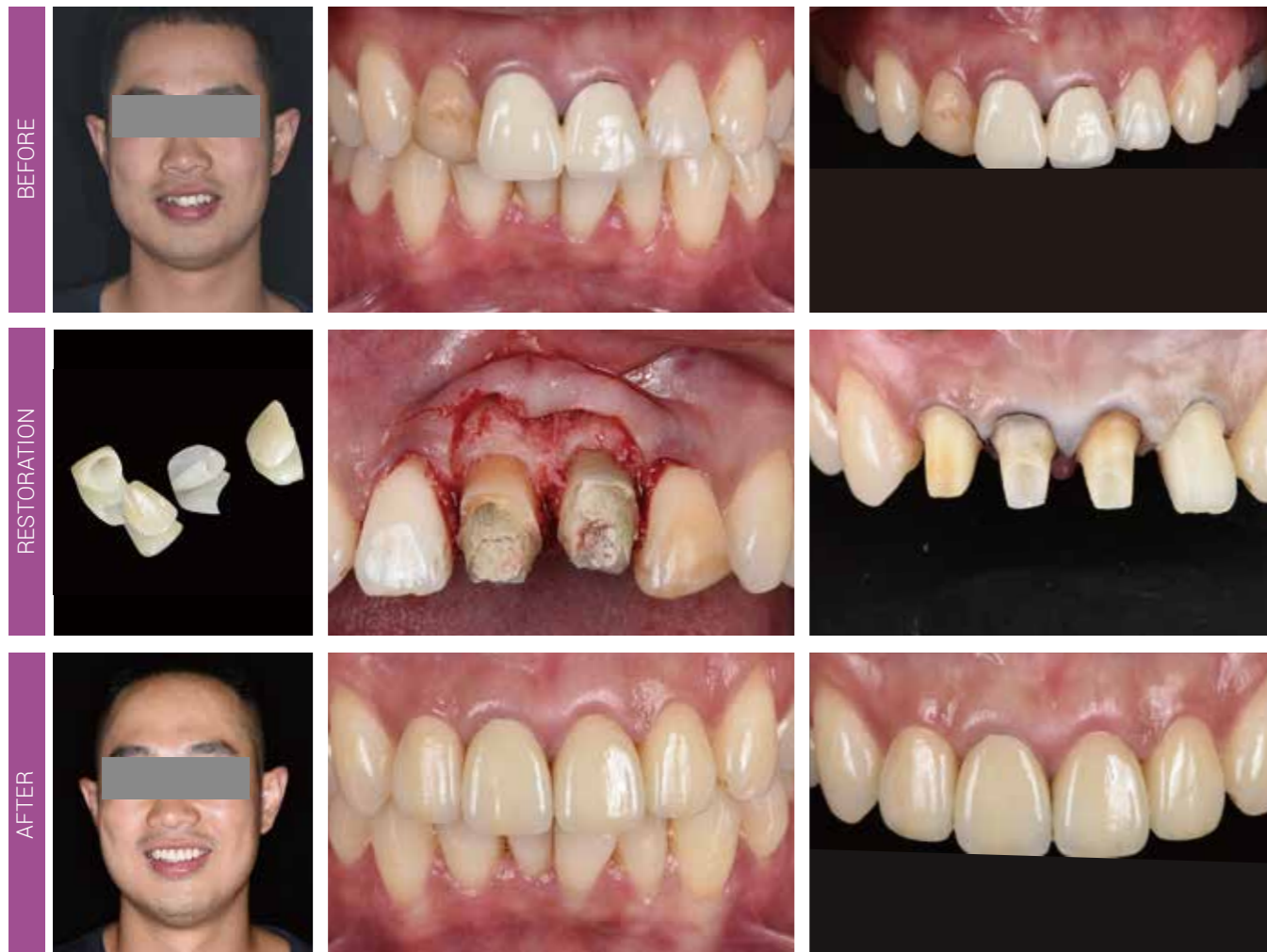History of present illness: Patient receive PFM crowns 10 year ago due to crown fracture on upper anterior teeth. The crown de-bonds recently and leads to unpleasant smiles.

Examination: 12 teeth discoloration, percussion pain (-), no loosening; 11, 21 teeth prepared body shape, percussion pain (-), no loosening; The height of the gingival margin of 11 and 21 is not coordinated, and the width of teeth of 12, 11, 21 and 22 is not coordinated. X-ray 12, 11, 21 imperfect root management treatment, low-density apical image.

Diagnosis: 12, 11, and 21 apical periodontitis, 12, 11, and 21 teeth defect.

Treatment plan: 12, 11, 21 root canal treatment + crown lengthening + post-core crown repair.

Material selection: Glass ceramics (lithium disilicate, Upcera, China).



EXPERT REVIEW

Xiaodong Chen | Dalian City Dental Hospital



Professor / Chief dentist / Dean
Member of the Chinese Association of Stomatology
Member of the Standing Committee of the Stomatologist Branch of the Chinese Medical Doctor Association, Academician of the International College of Dentistry
Member of the Standing Committee of CSED
Member of the Standing Committee of the Professional Committee of Prosthodontics, Chinese Association of Stomatology
Vice President of Liaoning Provincial Stomatological Association, former Chairman of Professional Committee of Prosthodontics of Liaoning Provincial Stomatological Association
Chairman of the Oral Aesthetics Professional Committee of the Liaoning Stomatological Association
Chairman of Dalian Medical Association Dental Specialist Branch
Director of Dalian Dental Medical Quality Control Center

Comments:

1. This case reported a second restoration for a failure restoration for anterior teeth. The harmonious and natural beauty of the "white" aesthetics of the crown and the gingival "pink" was reproduced through a standardized aesthetic restoration process. The periodontal crown lengthening procedure standardized by clinicians obtains the ideal gingival margin position, ceramics crown, veneer tooth preparation obtains the ideal restoration space, and the technician's exquisite skill realizes the aesthetic reproduction of porcelain materials. Through dentist and technician collaboration, a coordinated and consistent color aesthetic effect was obtained under different types of ceramics restorations with different thicknesses.

What should be paid attention to is the influence of the lower anterior teeth malalignment on the occlusal contact distribution and incisal guidance of the anterior teeth, which should be fully considered in the occlusal design and reproduction.

2. In this case, lithium disilicate glass ceramics commonly used in all-ceramic crowns of anterior teeth were selected, and feldspathic porcelain was added to the labial surface of the restoration to reproduce the color level and translucency aesthetic effect similar to that of natural teeth. Due to the high transparency of lithium disilicate glass ceramics, attention should be paid to the color of the abutment in clinical selection to avoid the "gray" aesthetics of the crown after restoration.



UP.Press

- Excellent All Ceramics Esthetic Restoration
- Natural & Lifelike Color



Xiao Zeng | Stomatological Hospital of Guizhou Medical University

Dentist

Member of Guizhou Provincial Oral Prosthodontics Committee and Oral Implant Committee

Basic information of the patient Gender: Female Age: 57 years old

Chief complaint: The length of the upper anterior teeth is inconsistent, and there are unsightly gaps that are requiring restoration treatment.

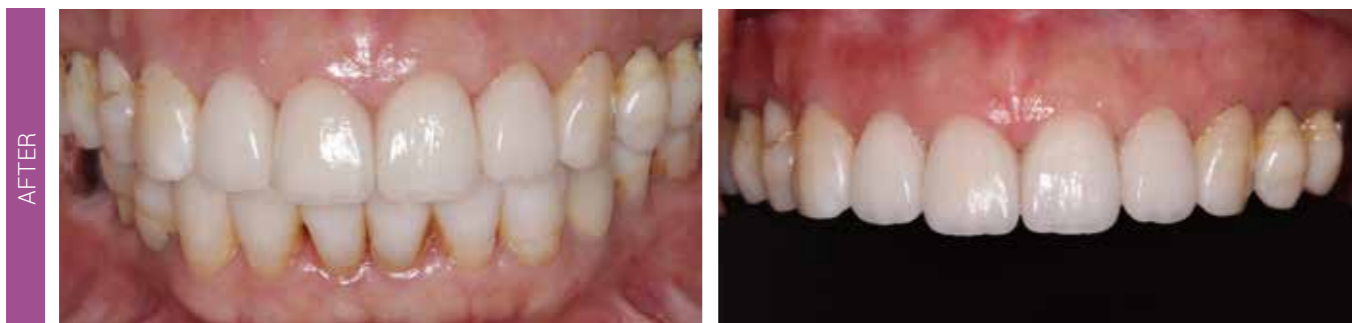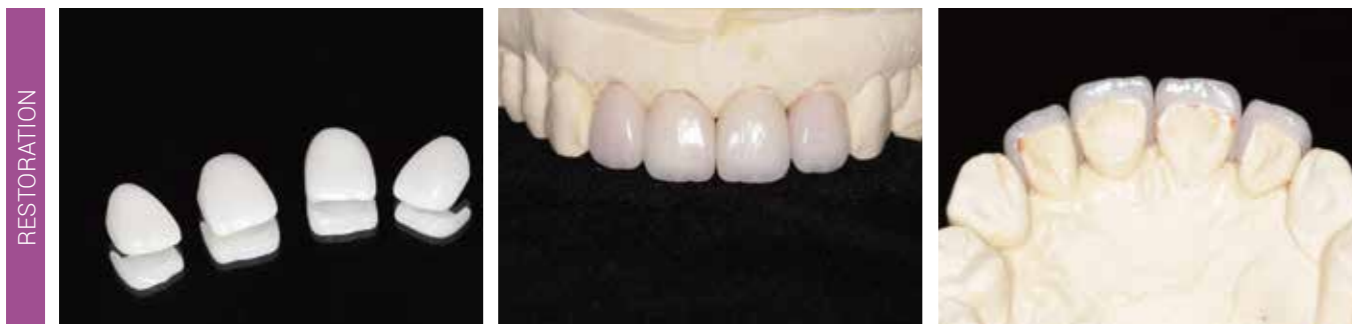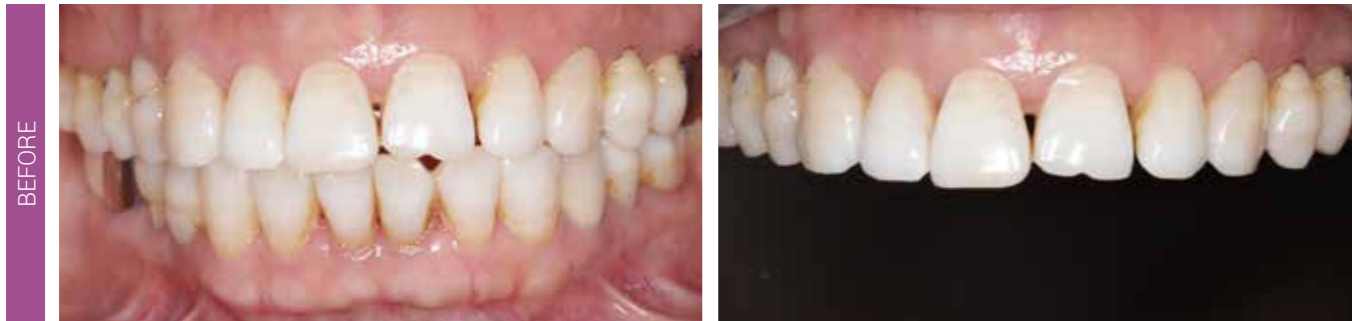History of present illness: Many years ago, it was discovered that the upper left anterior teeth were short and there were gaps between the teeth.

Examination: Number 21 is 1.5-2mm shorter than the neighboring teeth, and there is a gap with the neighboring teeth. The embrassures between the 12-22 teeth have "black triangles" and are stained.No obvious loosening and percussion pain.

Diagnosis: 21 tooth defects; interdental spaces between 11, 21 and 22.

Treatment plan: 12-22 veneer restoration.

Material selection: Glass ceramics (lithium disilicate, Upcera, China).



EXPERT REVIEW

Jianguo Tan | Peking University School of Stomatology

Professor / Chief dentist / Doctoral Supervisor

Minister of Continuing Education Department of Chinese Stomatological Association

Founding Chairman and Current Vice Chairman of CSED

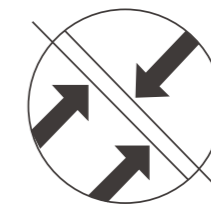
Member of the Standing Committee of the Prosthodontics Professional Committee of the Chinese Association of Stomatology

Executive director of Beijing Medical Aesthetic Specialist Branch

Member of American Society of Fixed Prosthodontics (AAFP)

Comments:

1. The patient's upper anterior teeth have mild defects in the shape and color of the teeth. The use of minimally invasive porcelain veneers can improve the shape and color of the teeth and improve the interdental space at the same time.
2. When the veneer is used to improve the tooth gap between 21 and 11, and between 21 and 22, the interproximal extended type veneer can be designed to close the tooth gap while restoring a good adjacent contact relationship and avoiding the "black triangle" .
3. The color of the abutment preparation after minimally invasive tooth preparation is basically normal without obvious shading requirements. The material for the porcelain veneer is made of glass ceramic with ultra translucency which results in satisfactory aesthetic effects.



**STRENGTH
400MPa**



Hao Wang | Tongren Street Community Health Service Center, Xuanwu District, Nanjing

Dentist

Basic information of the patient Gender: Female Age: 52 years old

Chief complaint: Request for aesthetic restoration of anterior teeth.

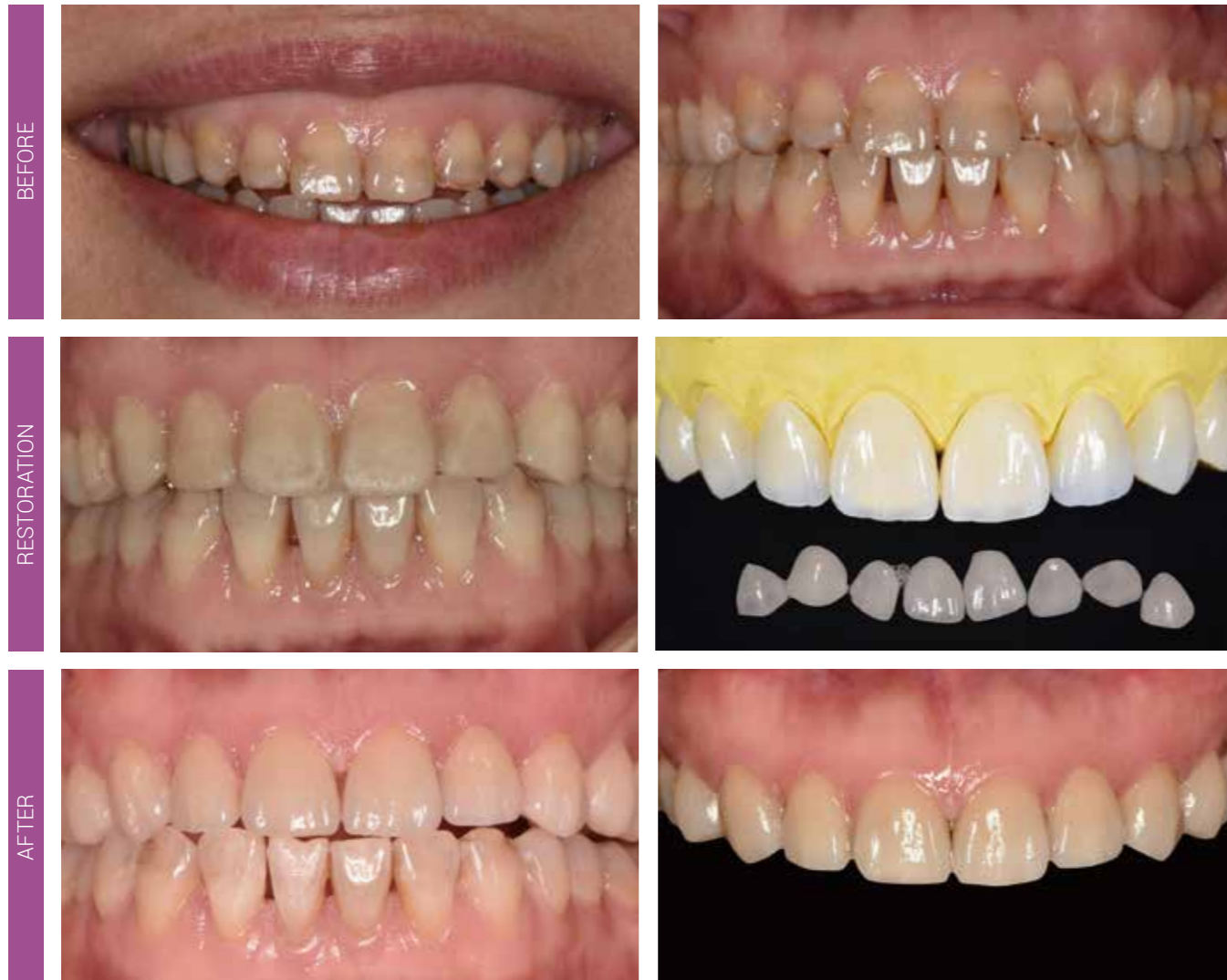History of present illness: Resin restoration of upper anterior teeth, discoloration, unsatisfactory morphology, and aesthetic veneer restoration is required.

Examination: High smile line, mild overjet and overbite; anterior tooth resin restoration, with poor esthetics.

Diagnosis: Tetracycline Discoloration.

Treatment plan: 14-24 porcelain veneer restoration.

Material selection: Glass ceramics (lithium disilicate, Upcera, China).



EXPERT REVIEW

Xu Gao | School of Stomatology Shandong University



Chief dentist / Director of Prosthodontics Department

Reviewer of "Stomatology" magazine

Expert of medical accident appraisal of Shandong Provincial Health and Family Planning Commission

Expert of project review of Shandong Provincial Department of Science and Technology Member and Secretary of CSED

Member of the Standing Committee of the Oral Prosthodontics Committee of the Chinese Association of Stomatology

Vice Chairman of Oral Prosthetics Professional Committee of Oral Plastic Surgery Branch of China Plastic Surgery Association

Vice Chairman of Shandong Provincial Oral Aesthetics Committee

Member of Standing Committee of Shandong Oral Prosthetics Professional Committee

Comments:

1. Dr. Wang Hao's case was a poor color of tetracycline teeth with enamel hypoplasia. After minimally invasive restoration-porcelain veneer restoration, the final aesthetic effect was quite satisfactory. However, it can be seen from the photos that the left and right upper teeth are edge-to-edge incisors, and the veneer is easy to fall off after restoration, so occlusal adjustment is vital.

In addition, the mesial restoration of the two central incisors is insufficient, forming a black triangle. The diagnosis result should be tooth defect (tetracycline with enamel hypoplasia).

2. The all-ceramic material selected in this case is lithium disilicate reinforced glass ceramics, which has gorgeous translucency, relatively high mechanical strength and ideal adhesion. The joint effect can meet the anterior tooth restorations (veneers, all-ceramic crowns) with higher aesthetic requirements.

